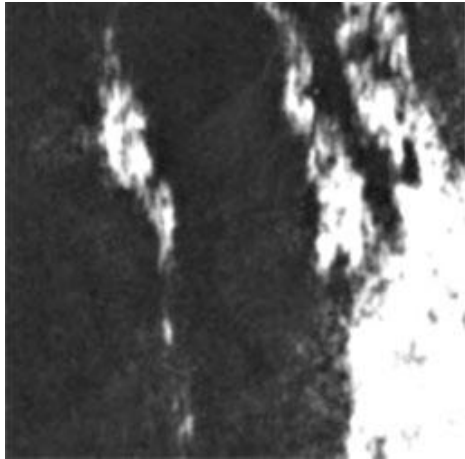
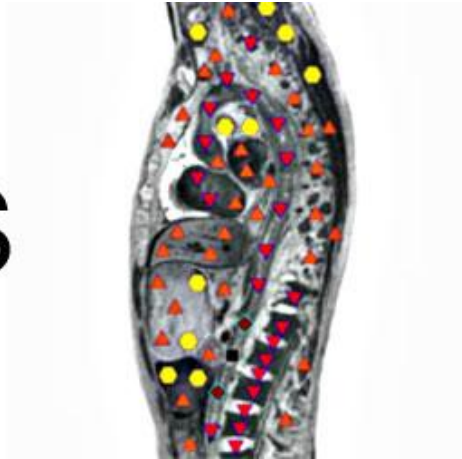




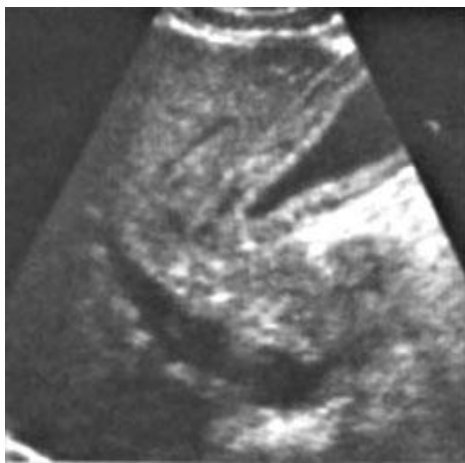Patient D., 56. Longitudinal section: stenosis of the abdominal aorta as a result of a blood clot, which is located next to the partially calcified athermanous plaque



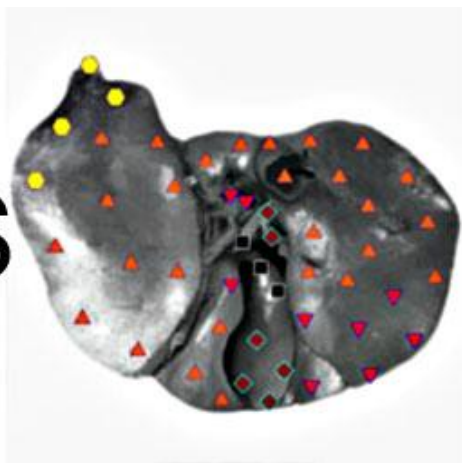
VS



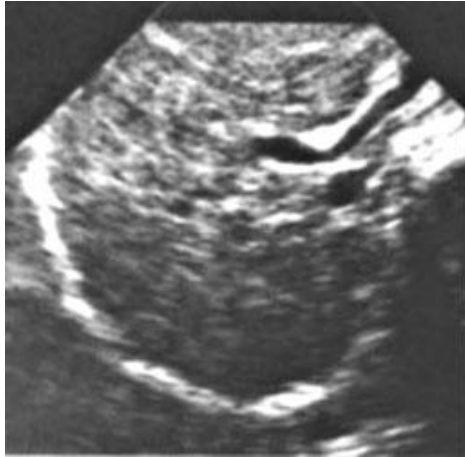Patient S., aged 48. Cross section: swelling of the gallbladder wall in normal parenchyma of the liver. The patient has acute hepatitis




VS



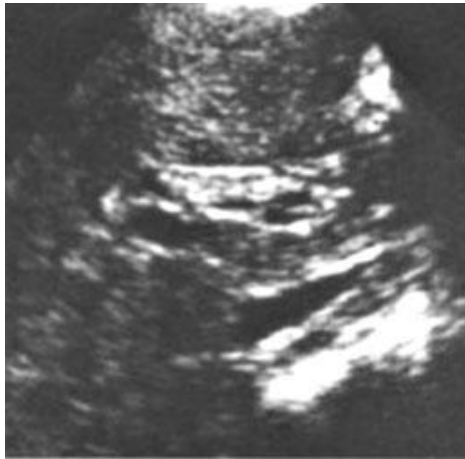Patient G., 44 years old: Cirrhosis



VS



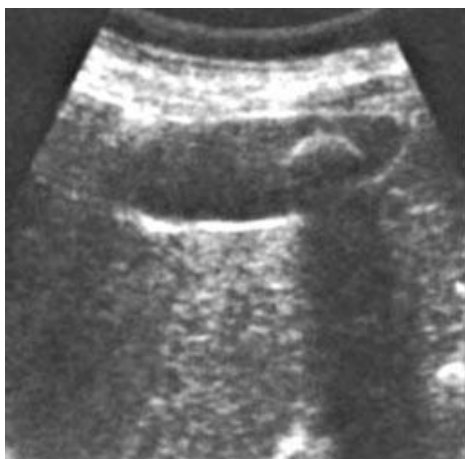Patient J., age 8. Longitudinal section: Ascaris in the common bile duct



VS



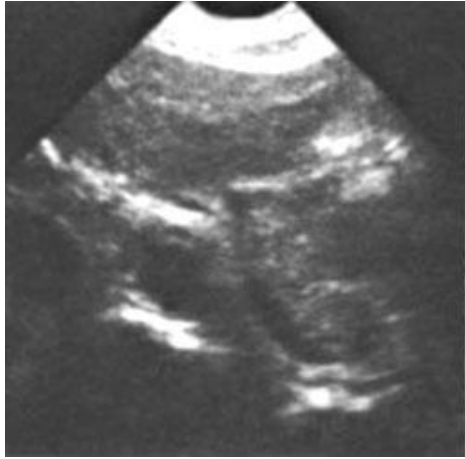Patient P. aged 36: The gall bladder contains a single large concretion



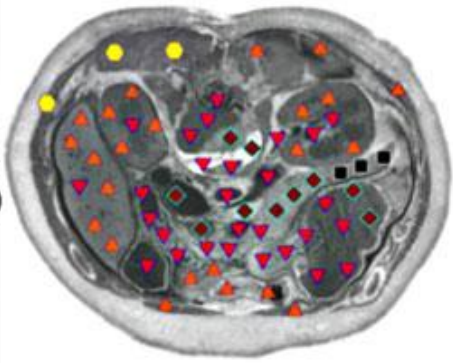
VS



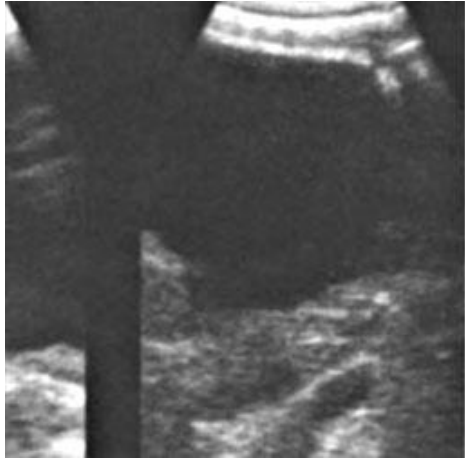Patient S., 84 years old: Atrophy of the tail of the pancreas



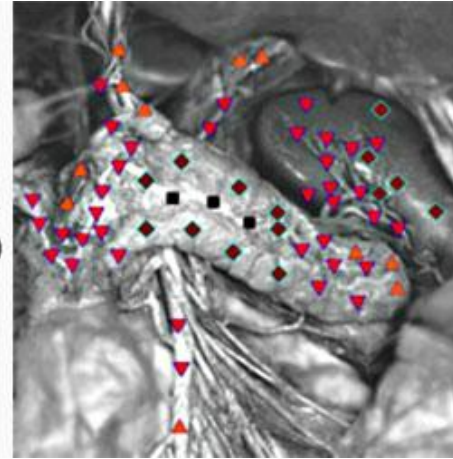
VS



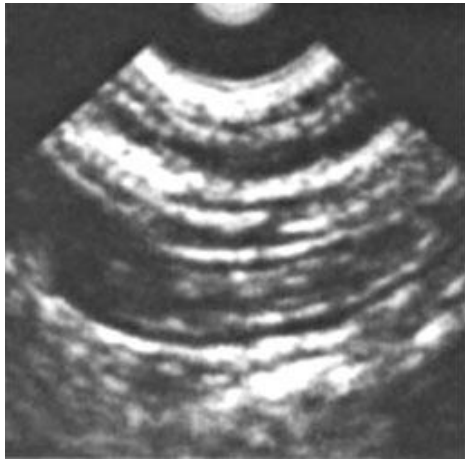Patient A., aged 68. Longitudinal sections: cysts in the pancreas



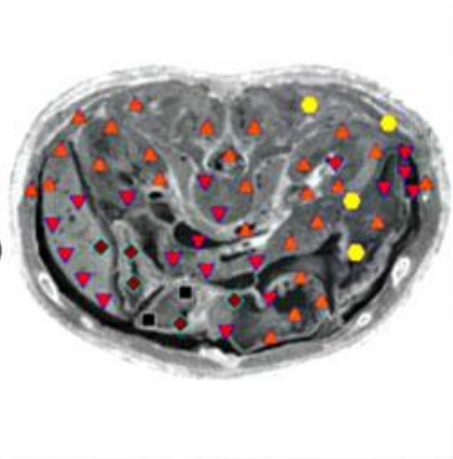
VS



Patient G., 34 years old. Cross section: erosive gastritis

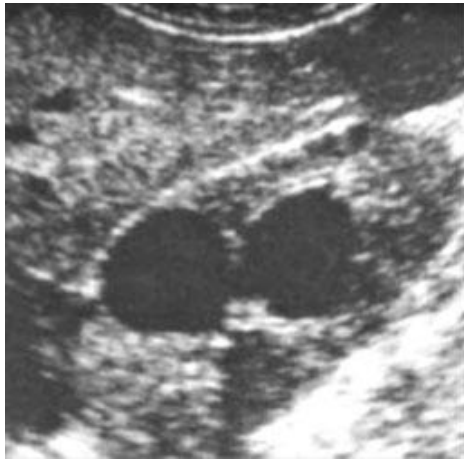

VS

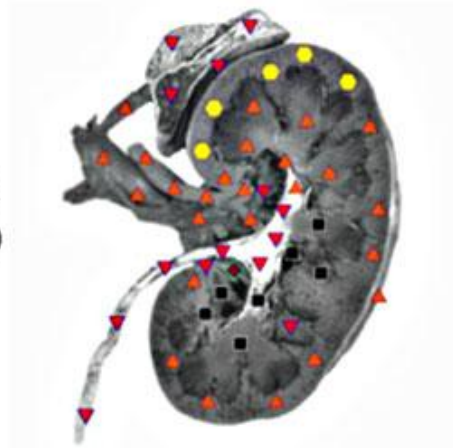

E. The patient, 42 years old. Longitudinal section: multiple cysts kidney

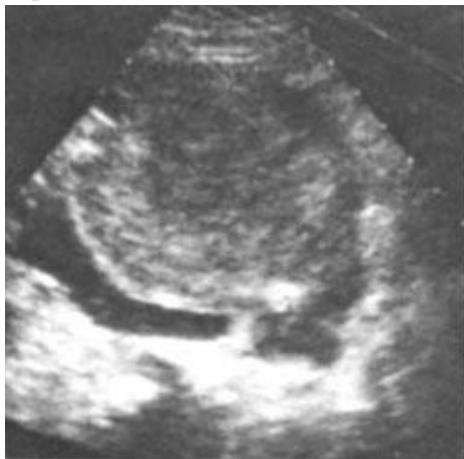



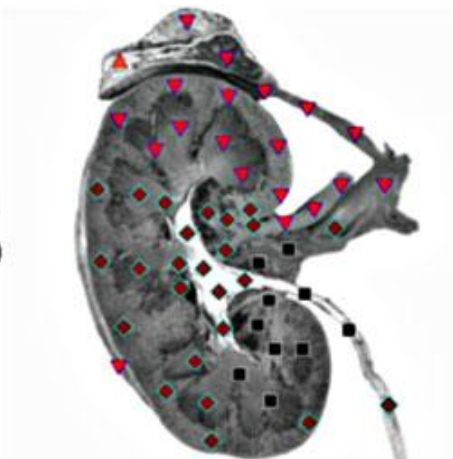
VS



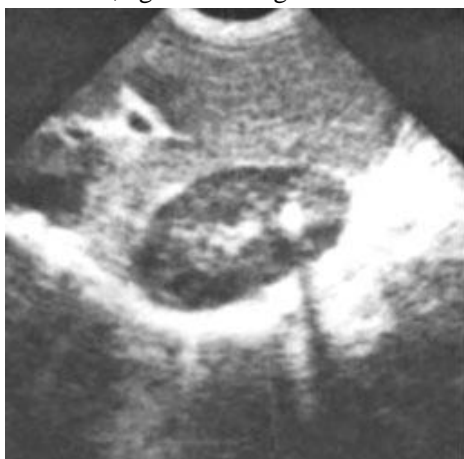Patient G., 34 years old. Cross section: erosive gastritis. Patient V., aged 68. Cross-section of a tumor of the lower pole of left kidney, ureter left in germinating and causing obstructive hydro nephritis



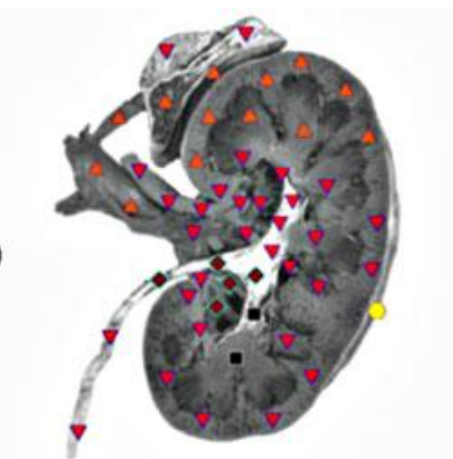
VS



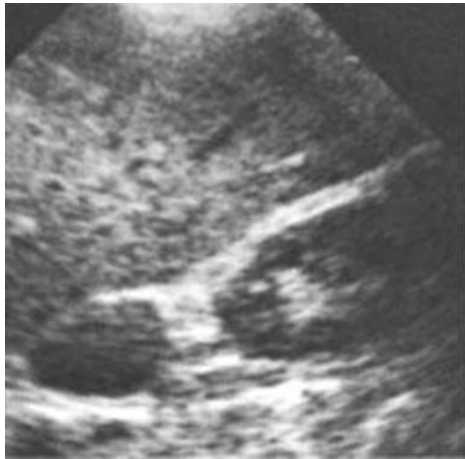Patient S., aged 56. Longitudinal section: right kidney stone



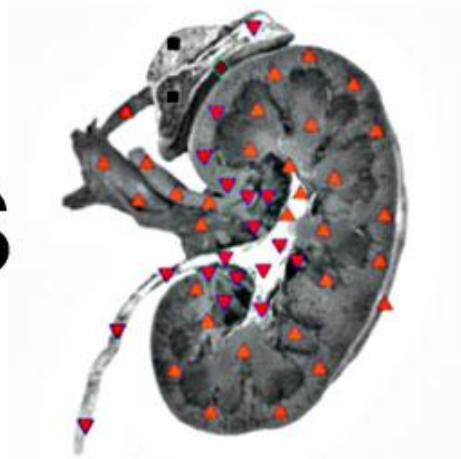
VS



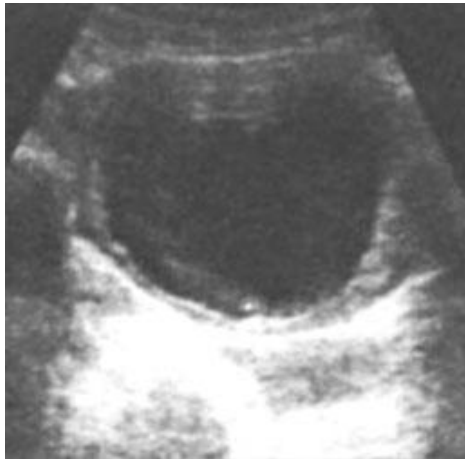Patient I., 65. Longitudinal section: benign adenoma in the right adrenal gland



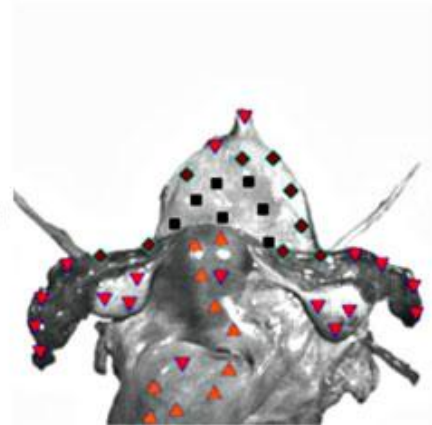
VS



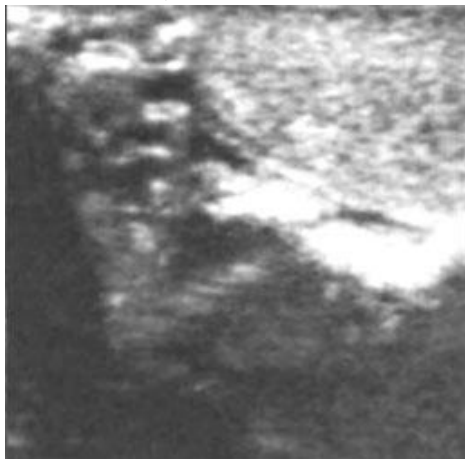
Patient K., 38 years old: Chronic inflammation of the bladder (chronic cystitis)



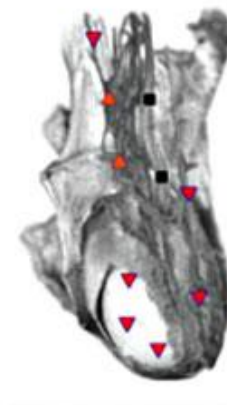
VS



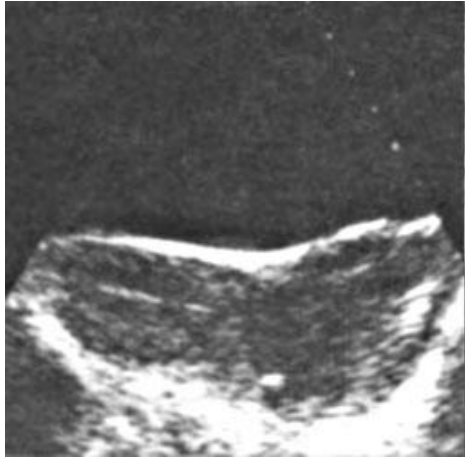
Patient G., 34 years old. Cross section: varicocele with multiple dilated veins



VS



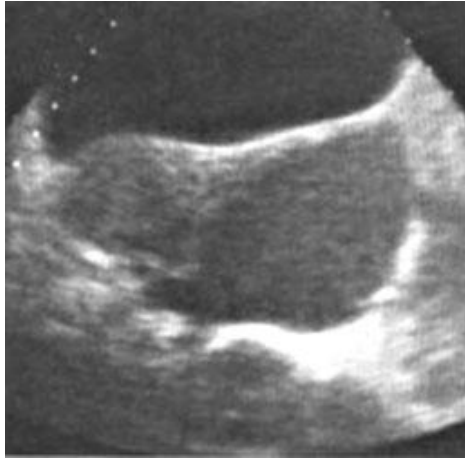Patient T., aged 46. Longitudinal section: a large tumor (cancer) of the cervix



VS



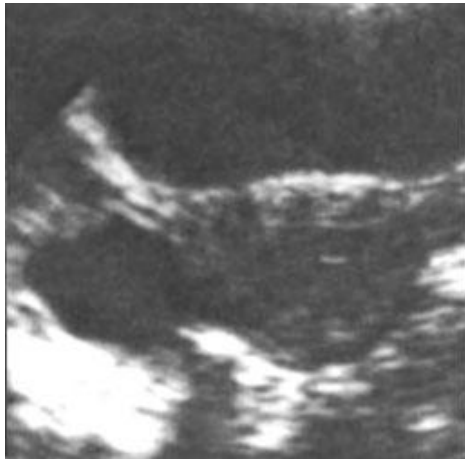
Patient M., 32 years old: Cross section: endometrium



VS



Patient D, 41. Cross section: ovarian cyst with smooth contours



VS

